



Available online at  
**ScienceDirect**  
[www.sciencedirect.com](http://www.sciencedirect.com)

Elsevier Masson France  
**EM|consulte**  
[www.em-consulte.com/en](http://www.em-consulte.com/en)



Original article

## DiscoGel<sup>®</sup> in patients with discal lumbosciatica. Retrospective results in 25 consecutive patients<sup>☆</sup>



A. Léglise<sup>a,\*</sup>, J. Lombard<sup>b</sup>, A. Moufid<sup>a</sup>

<sup>a</sup> Service de chirurgie orthopédique et traumatologique, CHU La Milétrie, 2, rue de La Milétrie, 86000 Poitiers, France

<sup>b</sup> Service de chirurgie orthopédique et traumatologique, centre hospitalier Georges-Renon, 40, avenue Charles-de-Gaulle, 7900 Niort, France

### ARTICLE INFO

#### Article history:

Received 22 July 2014

Received in revised form

31 December 2014

Accepted 11 May 2015

#### Keywords:

Lumbosciatica

Percutaneous

DiscoGel<sup>®</sup>

### ABSTRACT

**Introduction:** Discogenic lumbosciatica is a common disorder in patients between 30 and 40 years old. Because of the frequency and socio-professional impact of this entity, it represents a real public health problem. DiscoGel<sup>®</sup> is a class III medical device used for nucleolysis to avoid discectomy. The goal of this study was to evaluate the effectiveness of this treatment in patients with discogenic lumbosciatica following unsuccessful conservative medical treatment.

**Materials and methods:** This is a retrospective, single-center study including 25 patients who were treated with DiscoGel<sup>®</sup> between 2010 and 2011 at Niort Hospital, France. The severity of lumbar and radicular pain was assessed by a verbal numeric scale (VNS) and patient satisfaction. Patients were classified as successes or failures.

**Results:** Treatment was found to reduce the severity of lumbar pain in 73% and of radicular pain in 80% of patients in the success group. Treatment was a failure in 64% of patients. A comparison of the two groups showed that a preoperative MODIC 2 MRI signal of the adjacent vertebral end plate was significantly associated with treatment failure ( $\chi^2 = 8572$ ,  $P < 0.01$ ).

**Discussion:** The VNS for lumbar pain and radicular pain decreased in 42% and 50% of patients respectively after the use of DiscoGel<sup>®</sup>. In our series, DiscoGel<sup>®</sup> treatment was unsuccessful for discogenic lumbosciatica in 16 patients. These results do not support others in the literature. A lack of statistical power could partly explain these results. The most important result of this study is found in the subgroup analysis which suggests that indications for DiscoGel<sup>®</sup> treatment could be modified in the future in relation to preoperative imaging data.

**Level of evidence:** 4.

© 2015 Published by Elsevier Masson SAS.

## 1. Introduction

Common discogenic lumbosciatica is frequent in patients between 30 and 40 years old. Between 13% and 40% of the general population will experience an episode of sciatica during his/her life due to discoradicular conflict. Because of its frequency and socio-professional impact of this entity, it is a public health issue.

Percutaneous intradiscal techniques have been developed to provide treatment for discogenic lumbosciatica that is more effective than epidural infiltrations and less invasive than surgery. These techniques result in nucleolysis with a physicochemical action and nucleotomy with a physical action [1–3].

DiscoGel<sup>®</sup> is a class III intradiscal medical device composed of gelified ethanol associated with tungsten in suspension for nucleolysis. It is injected into the nucleus pulposus to reduce intradiscal pressure. The presence of cellulose, which is a gelling agent, limits the risk of epidural leaks that may occur with pure ethanol. The tungsten particles are used to control progression of the gel in the disc and through any annular fissures by fluoroscopic control. The mechanism of action of DiscoGel<sup>®</sup> is based on several hypotheses:

- decreasing intradiscal pressure because of the dehydration caused by injection of the product to decrease pain;
- lytic action on new nerve growth in the disc [4];
- necrotic action of alcohol on the nucleus pulposus [5].

In 2007, Théron defined the indications for DiscoGel<sup>®</sup> use in his study of 202 cases [6]. For this author, DiscoGel<sup>®</sup> is an alternative to surgical treatment of radicular pain from contained or

<sup>☆</sup> DiscoGel<sup>®</sup> Gelscom 8, avenue de Dubna ZAC CITIS F-14 200 Hérrouville-Saint-Clair.

\* Corresponding author.

E-mail address: [amelie.leglise@orange.fr](mailto:amelie.leglise@orange.fr) (A. Léglise).

**Table 1**  
Characteristics of the study population.

Total	25 patients, 9 women 16 men
Age	19–58 years old; mean age = 38.4
Mean pretreatment DRAD	
Daily activities	71%
Activités professionnelles	66%
Mean pretreatment lumbar VNS	5.17
Mean pretreatment radicular VNS	6.87
Topography of lumbosciatica	12 L5, 13 S1
Medical history of infiltration	5 foraminal infiltrations, 1 epidural infiltration
Interval between symptoms and treatment with DiscoGel®	1 month–24 months mean 7.8 months

uncontained herniated discs at the cervical or lumbar levels, that have been present for more than 3 months, are resistant to medical treatment with no neurological complications, and which have been confirmed by imaging techniques.

Twenty-eight patients in our center were treated with DiscoGel®. The goal was to evaluate the efficacy of treatment of lumbar radicular pain as well as to compare the success and failure treatment groups to identify any possible factors of failure.

## 2. Materials and methods

Twenty-eight patients, aged 19 to 58 were treated with DiscoGel® between 2010 and 2011 by the same operator in the same center (Niort Hospital, France).

The initial population included 10 women and 18 men presenting with clinical lumbosciatica due to median, paramedian or foraminal subligamentous herniated discs on imaging.

Inclusion criteria were a clinical picture of discal lumbosciatica that was resistant to appropriate conservative medical treatment and confirmed by imaging. Exclusion criteria were a history of surgery of the spine at the involved levels and/or imaging results that did not support the clinical results, the presence of a herniated disc excluded on imaging, involvement of several levels and/or incomplete data collection.

The severity of lumbar and radicular pain was evaluated by a verbal numeric scale (VNS, 0 = no pain; 10 = maximum pain) before treatment and at the postoperative consultation between D30–D45 after injection of DiscoGel® to define the variation in the VNS as a result of treatment.

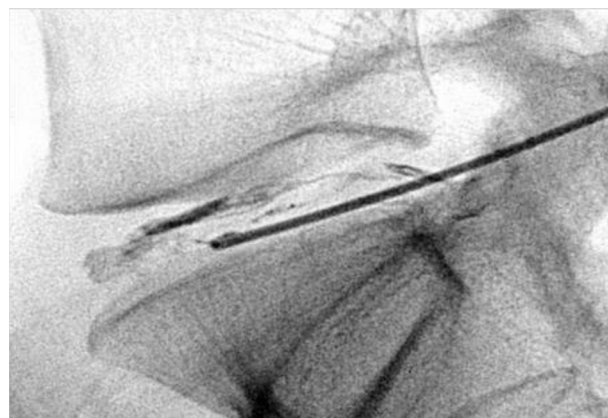Patients were contacted by telephone to determine their level of satisfaction with treatment. The patient was asked to rate the outcome of treatment as poor/mediocre/satisfactory/very satisfactory/excellent; and in case of failure to know if additional treatment had been necessary. Seven of the 28 patients could not be reached by telephone, and these data were obtained from the elements in the medical file during the different consultations. Three files were excluded from analysis due to lack of data.

The standardized DRAD questionnaire (Dallas pain self-evaluation [7]) was used to evaluate the repercussions of lumbosciatica on daily and professional activities before and after DiscoGel® treatment.

The characteristics of the study population are presented in Table 1.

Patients were classified into 2 groups:

- in the success group if the VNS decreased by >50% and the patient was satisfied;
- in the failure group if the VNS decreased by ≤50% and/or the patient was dissatisfied.



**Fig. 1.** (Ph Brunner); DiscoGel® injection.

Satisfaction with DiscoGel® treatment was classified as:

- poor;
- mediocre;
- average;
- good;
- very good;
- excellent.

Patients who responded poor, mediocre or average were considered to be dissatisfied with treatment while those who responded good, very good or excellent were considered to be satisfied.

Treatment was considered to have failed in the following situations:

- decrease in VNS < 50%;
- patients who underwent a secondary procedure (infiltration or surgery);
- patients who classified the results of treatment as poor, mediocre or average even if they did not undergo a secondary procedure.

The study population was divided into two groups based on the results: patients for whom the DiscoGel® procedure was successful and those for whom it was a failure. These two groups were analyzed and compared to identify any prognostic factors of failure.

The DiscoGel® injection protocol was the following (Figs. 1 and 2):

- outpatient procedure;
- in the surgical block under strictly aseptic conditions;
- under local and neuroleptic anesthesia;
- with the patient lying on the stomach;
- under fluoroscopic control;
- 18G needle;
- slow percutaneous injection of DiscoGel® 0.1 mL/30 seconds;
- progression of the product controlled by fluoroscopy;
- a single operator;
- with three hours of postoperative surveillance.

## 3. Results

There were no complications during the procedure, and no leaking of the product. Fifteen of the 25 patients (60%) seen at follow up were on sick leave at the first postoperative consultation due to lumbosciatica pain.

Treatment with DiscoGel® was considered to be a failure in 16 patients, or 64% of the population. Fourteen of these 16 failures underwent secondary treatment. A total of 56% of the population

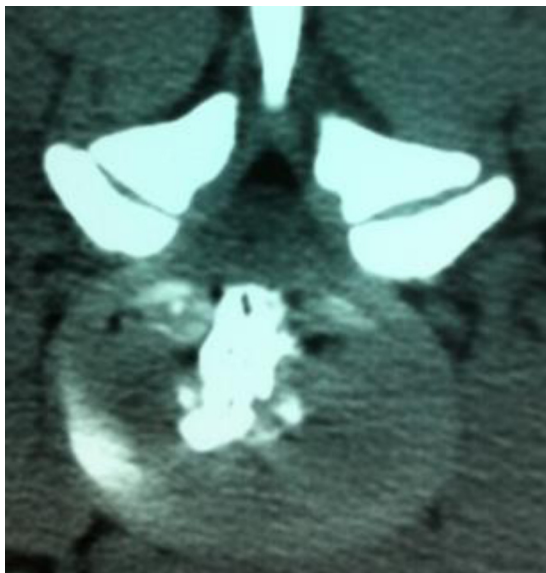

Fig. 2. (Ph Brunner): mode of injection.

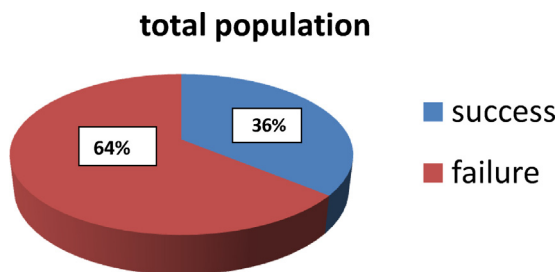


Fig. 3. Results of treatment in the study population.

underwent either foraminal infiltration, a cure for a herniated disc or arthrodesis. Two out of 16 failures did not undergo secondary treatment but rated the DiscoGel® treatment as mediocre or poor, respectively.

The VNS for lumbar pain in the 25 patients who were evaluated in the study went from 5.17 to 3.00 or a decrease of 42%. The VNS for radicular pain went from 6.87 to 3.43 or a decrease of 50%. Nevertheless, the decrease in VNS was still ≤50%, the threshold chosen for the treatment to be considered a success (Figs. 3 and 4).

Two groups can be identified in this study:

- a group of 9 patients in whom DiscoGel® was a success because the lumbar and radicular VNS decreased by >50% AND the patient was satisfied with treatment;

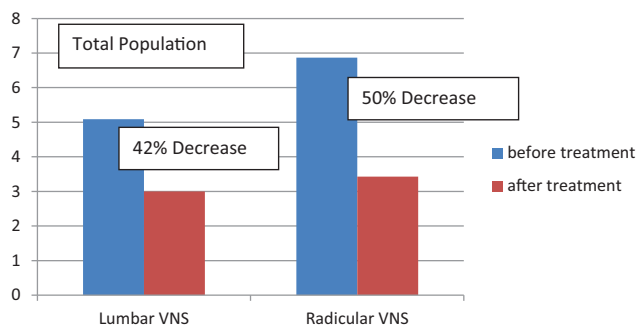


Fig. 4. Variation in lumbar and radicular VNS before and after treatment for the entire study population.

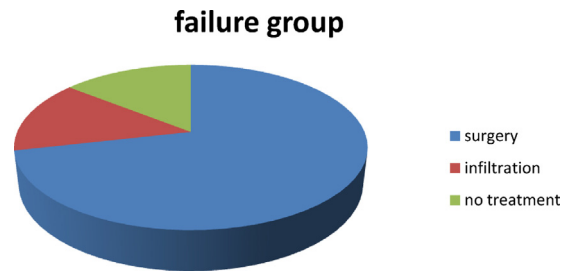


Fig. 5. Secondary treatments in the failure group.

- a group of 16 patients in whom DiscoGel® treatment was a failure because the lumbar and radicular VNS decreased by ≤50% and/or the patient stated that s/he was dissatisfied.

In the group in which treatment failed 12/16 patients underwent secondary surgery (Fig. 5.pdf). The characteristics of the two groups are presented in Table 2.

In the satisfied group, the decrease in VNS for lumbar pain was 73% and for radicular pain was 80% compared to the dissatisfied group in which the lumbar VNS decreased by 21% and the radicular VNS by 26% (Fig. 6).

There were more men in the success group, but this difference was not significant. On the other hand, a significant number of patients had a MODIC 2 sign in the failure group ( $\chi^2 = 8.572$ ,  $P < 0.01$ ). In other words, a disc with fatty degeneration was associated with failure of DiscoGel® treatment. We did not find any other significant factors to explain our failures.

#### 4. Discussion

DiscoGel® is a new minimally invasive therapeutic technique for the treatment of discogenic lumbosciatica and an alternative to invasive surgery in case of unsuccessful medical treatment.

Table 2 Characteristics of 2 subgroups.

	Satisfied group n = 9	Dissatisfied group n = 16
Population	1 woman, 8 men	8 women, 8 men
Mean age	38.2	38.5
VNS before	Lumbar VNS = 4.88 Radicular VNS = 6.66	Lumbar VNS = 5.21 Radicular VNS = 7.00
VNS after	Lumbar VNS = 1.33 or a 73% decrease Radicular VNS = 1.33 or a 80% decrease	Lumbar VNS = 4.07 or a 21% decrease Radicular VNS = 5.21 or a 26% decrease
Levels of lumbosciatica	5 L5 4 S1	8 L5 8 S1
MODIC	<b>0 = 3 patients</b> <b>1 = 6 patients</b> <b>2 = 0 patients</b>	<b>0 = 2 patients</b> <b>1 = 4 patients</b> <b>2 = 10 patients</b>
PFIRMANN	1 = 1 patient 2 = 1 patient 3 = 5 patients 4 = 2 patients	1 = 2 patients 2 = 1 patient 3 = 6 patients 4 = 5 patients
Discal narrowing	None or less than 50% = 9 >50% = 0	None or less than 50% = 15 >50% = 1
Interval pain-treatment	9.3 months	8 months
DRAD daily activities		
Pretreatment	65.3%	73.4%
Post-treatment	12%	62.3%
DRAD professional	85%	85%
Post treatment	10%	75%
Sick leave	44%	69%

Data in bold correspond to significant differences.

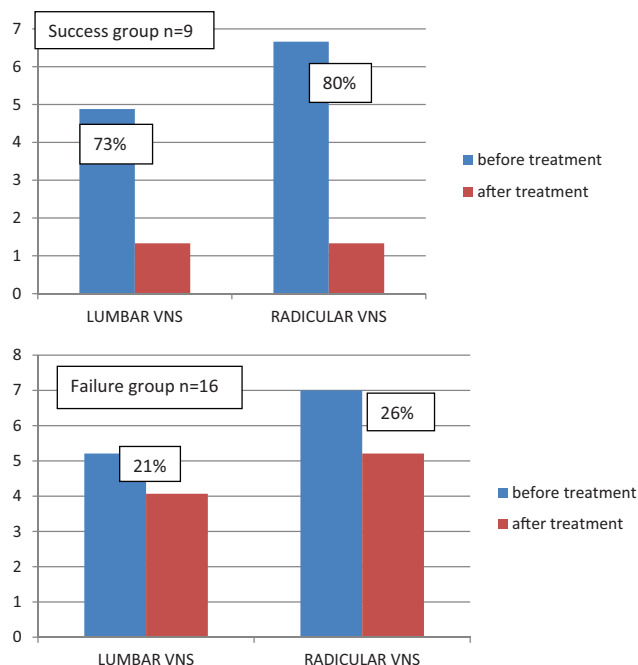


Fig. 6. Decrease in VNS in the success and failure groups.

Initial studies performed by Theron and De Seze found a success rate of 91% and 75% with DiscoGel® [6,8]. Different studies have also reported that the severity of lumbar and radicular pain decreased by 80 to 85% with chemopapaine [9–13] and by approximately 70% with replacement techniques [2,3].

In the success group the severity of lumbar and radicular pain improved by approximately 73% and 80% respectively, which corresponds to the results of other studies in the literature. Moreover, in previous studies patients eligible for DiscoGel® treatment have been shown to have the following characteristics: men with a narrow lumbar canal, injury at L4–L5 and at only one level, with no pain during coughing, no narrowing of the disc space and symptoms for less than 1 year. Our success group corresponds to these eligibility criteria because it included mostly men who presented with lumbosciatica that had been present for less than a year, involving a single level. The mean period of time between pain and treatment was 9 months in the success group and 8 months in the failure group; these results are fairly similar to those in the literature (4 months for Theron et al. and 14 months for De Seze et al.).

On the other hand, the global analysis of our series does not support the results in the literature because our failure rate was 64%. These results can be explained by the small size of the study resulting in a methodological weakness and a lack of statistical power. The high rate of failures may also be explained by the procedure itself, which was not associated in this study with an injection of cortisone as in the study by Theron et al. [6].

However, despite the small size of the study it seems clear that there is a correlation between the preoperative MODIC 1 MRI

signal and treatment efficacy. In our study, the presence of fatty disc degeneration, presenting as a preoperative MODIC 2 MRI signal was significantly associated with failure. None of the existing studies have taken into account this factor, which our results seem to indicate is a potential prognostic parameter of treatment failure. Treatment with DiscoGel® is being evaluated and is an alternative to invasive procedures, which is why it is so important to determine its specific field of action.

## 5. Conclusion

DiscoGel® is an effective treatment for discogenic lumbosciatica. The high rate of failures in our study was significantly related to the presence of peridiscal fatty degeneration (MODIC 2). Further studies are therefore needed to confirm this hypothesis in a larger group and to confirm this feature as a potential prognostic factor of treatment failure.

## Disclosure of interest

The authors declare that they have no conflicts of interest concerning this article.

## References

- [1] Bontoux D, Alcalay M, Debais F, et al. Traitement des hernies discales par injection intra-discale de chymopapaine et d'hexacétionide de triamcinolone, étude comparative de 80 cas. *Rev Rhumatol* 1990;57:327–31.
- [2] Dupuy R, Lavignolle B, Vignes R. Traitement de la lombosciatique par nucleotomie laser : à propos de 56 patients suivis 12 mois. *Rachis* 2003;15:321–7.
- [3] Paradiso R, Alexandre A. The different outcomes of patients with disc herniation treated either by microdiscectomy, or by intradiscal ozone injection. *Acta Neurochir Suppl* 2005;92:139–42.
- [4] Freemont AJ. Nerve ingrowth into diseased intervertebral disc in chronic back pain. *Lancet* 1997;350(9072):178–81.
- [5] Riquelme C, Tournade A. Chimonucleolysis of lumbar disc herniation with ethanol. *J Neuroradiol* 2001;28(4):219–29.
- [6] Theron J, Guimaraens L, Casasco A, et al. Percutaneous treatment of lumbar intervertebral disk hernias with radiopaque gelified ethanol: a preliminary study. *J Spinal Disord Tech* 2007;20:526–32.
- [7] Wilhelma F, Fayolle-Minona I, Phanera V, Le-Quanga B, Rimauda D, Béthoux F, et al. Sensitivity to change of the Quebec Back Pain Disability Scale and the Dallas Pain Questionnaire. *Ann Phys Rehabil Med* 2010;53(1):15–23.
- [8] de Seze M, Saliba L, Mazaux JM. Percutaneous treatment of sciatica caused by a herniated disc: an exploratory study on the use of gaseous discography and DiscoGel® in 79 patients. *Ann Phys Rehabil Med* 2013;56:143–54.
- [9] Kelekis A, Filippiadis DK. Percutaneous treatment of cervical and lumbar herniated disc. *Eur J Radiol* 2014. <http://dx.doi.org/10.1016/j.ejrad.2014.02.023>.
- [10] Marcia S, Bellini M, Piras E, Marras M, Ledda G, Sannia S, et al. Abstract No. 196: efficacy of DiscoGel® radiopaque gelified ethanol+etilcellulose in the treatment of contained disc herniations: a preliminary experience. *J Vasc Intervent Radiology* 2011;22(3 Suppl.):S85.
- [11] Dabezies EJ, Langford K, Morris J, Shields CB, Wilkinson HA. Safety and efficacy of chymopapain (discase) in the treatment of sciatica due to a herniated nucleus pulposus. Results of a randomized, double-blind study. *Spine* 1988;13:561–5.
- [12] Feldman J, Menkes CJ, Pallardy G, Chevrot A, Horreard P, Zenny JC, et al. Double-blind study of the treatment of disc lumbosciatica by chemonucleolysis. *Rev Rhum Mal Osteoartic* 1986;53:147–52.
- [13] Javid MJ, Nordby EJ, Ford LT, Hejna WJ, Whisler WW, Burton C, et al. Safety and efficacy of chymopapain (chymodiactin) in herniated nucleus pulposus with sciatica. Results of a randomized, double-blind study. *JAMA* 1983;249:2489–94.